

Anatomy of the larynx, trachea and bronchi

Ed Burdett

Viki Mitchell

Abstract

The anatomy of the airway is a core topic in anaesthesia, and a detailed knowledge is expected for examinations as well as in everyday practice. This article presents the most important aspects of airway anatomy from the point of view of the anaesthetist, with particular emphasis on understanding the clinical implications of the relevant structures and how they interact. The anatomy of the larynx and its innervation is discussed in detail, and put into clinical context as appropriate. Bronchial anatomy is described to aid navigation during bronchoscopy. Where possible, diagrams are used to help understanding.

Keywords Adult; airway; anaesthesia; anatomy; glottis; larynx; trachea

The larynx (Figures 1–4)

The larynx is the organ of phonation; it also assists in coughing and straining, and closes the respiratory system during swallowing, preventing aspiration. It develops from the fourth and sixth branchial arches. At the level of C3–C6, it is smaller and slightly higher in adult females than in adult males.

Bones and cartilages

There are nine cartilages in the larynx, but the hyoid is the only bone.

The U-shaped hyoid bone suspends the rest of the larynx. It does not directly articulate with any other bone; instead, it connects to the styloid process of the temporal bones by the stylohyoid ligament, and to the thyroid cartilage by the thyrohyoid membrane and muscle. The hyoid has a body, and greater and lesser horns, or cornua.

The laryngeal cartilages consist of the solitary thyroid, cricoid and epiglottis, and pairs of arytenoids, corniculates and cuneiforms. They are connected by joints and ligaments, which are known as folds when covered by mucus membrane.

The leaf-shaped epiglottis is situated between the superior laryngeal inlet and the base of the tongue. It is connected to the hyoid bone by the hyo-epiglottic ligament. Between the epiglottis and the base of the tongue is a pouch-like fold called the vallecula. It is into this that the tip of the correctly placed laryngoscope is inserted during direct laryngoscopy in adults.

Ed Burdett MA MRCP FRCA is a Consultant Anaesthetist in London, United Kingdom. Conflicts of interest: none declared.

Viki Mitchell FRCA is a Consultant Anaesthetist at University College Hospital, London, United Kingdom. Conflicts of interest: none declared.

Learning objectives

After reading this article you should be able to:

- draw and label a diagram of the larynx and its most important relations
- describe the clinical importance of the innervation of the larynx
- compare and contrast the anatomy of the left and right main bronchi

The shield-like thyroid cartilage is formed from the fusion of two quadratic laminae. The angle of fusion is more acute in the male (90°) than in the female (120°), which causes the vocal cords to be longer in the male, accounting for the deeper voice and the greater laryngeal prominence (Adam's apple) in men. The superior cornu of the thyroid cartilage is attached to the lateral thyrohyoid ligament, and the inferior cornu articulates with the cricoid cartilage at the cricothyroid joint. It is the articulation at this joint that maintains the tension with varying length of the vocal cords.

The cricoid cartilage is shaped like a signet ring at the base of the larynx. Since it is relatively strong, and is the only complete ring of cartilage in the airway, it is here that Sellick's manoeuvre is performed to prevent regurgitation during rapid-sequence induction. Its anterior component connects to the thyroid by the cricothyroid membrane, an avascular structure.

The arytenoid cartilages are in the posterior part of the larynx, and are shaped like three-sided pyramids. They articulate with the cricoid cartilage (see Figure 2) and control the tension of the vocal cords (see below). The cricoarytenoid joint is synovial and can therefore be affected by rheumatoid arthritis and systemic lupus erythematosus. Airway obstruction from involvement of these joints is a rare but serious complication of these disorders. The arytenoid cartilages connect with the epiglottis via the aryepiglottic folds.

The cuneiform and corniculate cartilages are embedded in the aryepiglottic folds between the epiglottis and arytenoids. They reinforce the folds and may assist in movement of the arytenoids. The cuneiforms are cylindrical and are anterolateral to the triangular corniculates. They can be seen as raised areas in the folds during laryngoscopy (see Figure 3).

Vocal cords

The vocal cords are made from the free upper edges of the cricothyroid membrane (conus elasticus) where it thickens to become the cricovocal ligament and is covered with mucosa. The mucosa is pearly white and has no submucosa; thus, it cannot become oedematous. Posteriorly, it is attached to the vocal process of the arytenoid cartilage, which forms the posterior 40% of the cords.

The cricothyroid membrane is attached circumferentially around the inside of the ring of the cricoid cartilage, and has a free upper inner margin which is attached anteriorly to the back of the thyroid via a membrane called Broyle's ligament cartilage, and posteriorly to the arytenoids. It is this free margin which forms the cords themselves. The mucosa of the vocal cords consists of squamous epithelium unlike the lining of the rest of

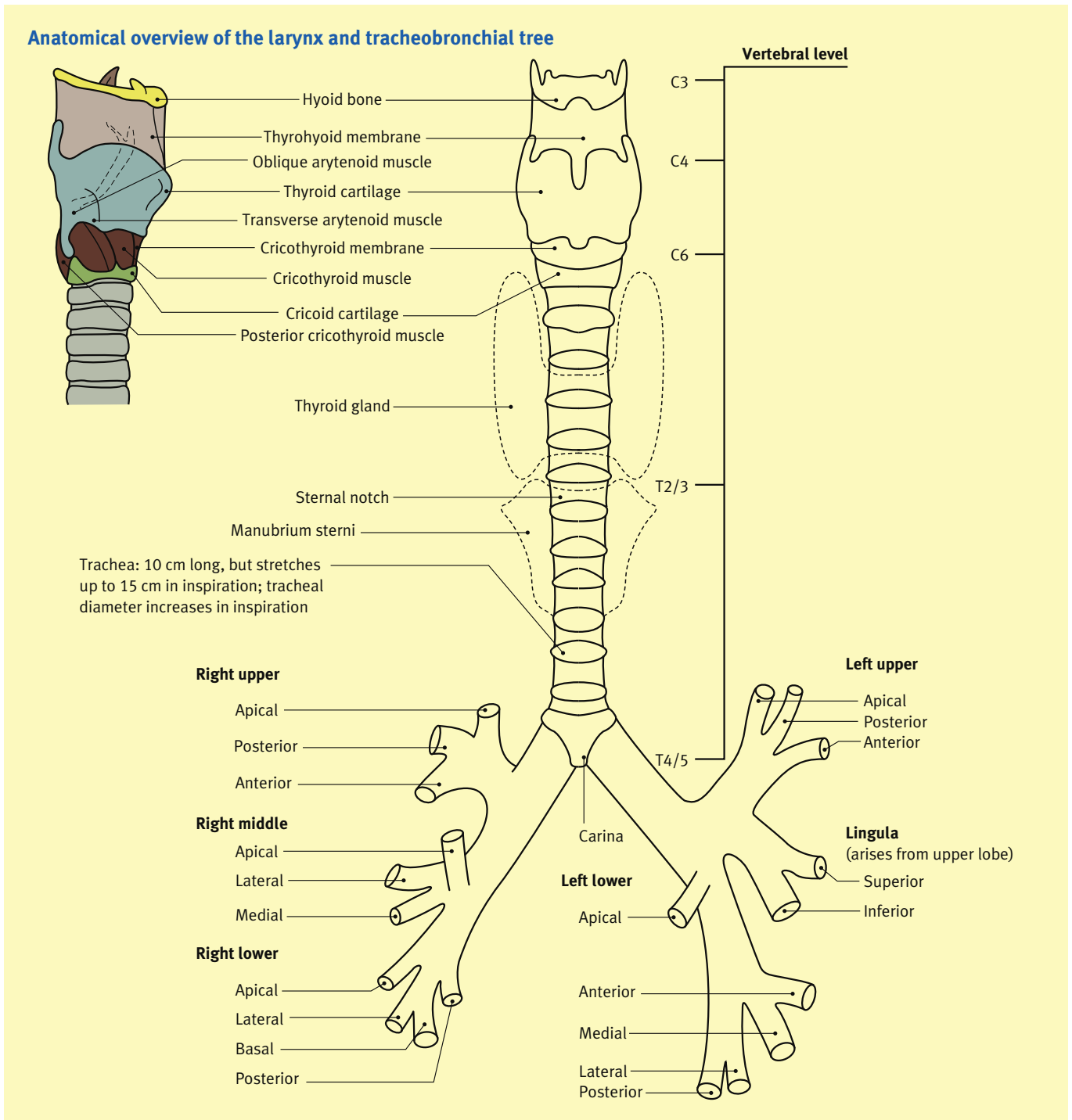


Figure 1

the larynx (and the respiratory tract), which is ciliated pseudo-stratified epithelium.

Muscles

The muscles can be divided into intrinsic and extrinsic muscles.

The extrinsic muscles can be further divided into suprahyoid muscles (stylohyoid, geniohyoid, mylohyoid, thyrohyoid digastric and stylopharyngeus), which can elevate the larynx, and

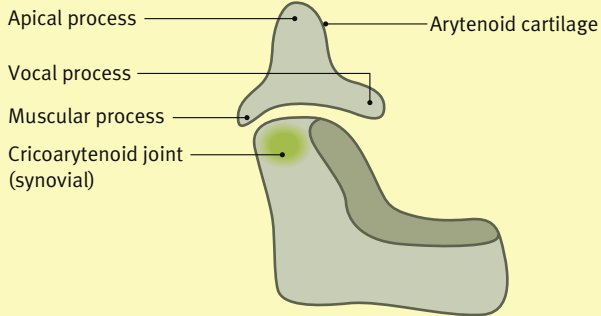
infrahyoid muscles (omohyoid, sternothyroid, sternohyoid and thyrohyoid), which lower the larynx and to a minor degree alter the laryngeal shape.

The intrinsic muscles control the vocal cords (see Figure 4). All intrinsic muscles of the larynx are supplied by the recurrent laryngeal nerve except for the cricothyroid, which is supplied by the external branch of the superior laryngeal nerve.

The cricothyroid is the only muscle that:

- tightens the cords

The arytenoid cartilage and its relation to the cricoid cartilage



Reproduced with permission from Whitaker RH, Borley NR. Instant anatomy. Oxford: Blackwell, 2005

Figure 2

- is supplied by the external branch of the superior laryngeal nerve
- is an intrinsic muscle of the larynx, but lies outside the larynx.

Nerve supply

Nerves supplying the intrinsic muscles of and sensation to the larynx originate from the vagus, via the superior and recurrent laryngeal nerves.

The *superior* laryngeal nerve separates from the vagus just outside the jugular foramen, at the inferior vagus ganglion. At the level of the hyoid, it subdivides into internal and external branches. The internal branch passes through the thyrohyoid membrane and provides sensory innervation up to the vocal cords; the external branch supplies the cricothyroid muscle.

The *recurrent* laryngeal nerve branches from the vagus in the thorax and loops around the arch of the aorta on the left and the subclavian artery on the right before travelling back up between the oesophagus and the trachea to supply all the intrinsic muscles of the larynx except the cricothyroid and sensation to the larynx below the vocal cords.

View of the larynx at laryngoscopy

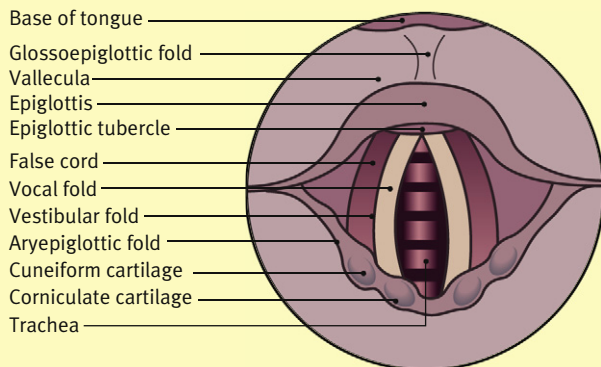


Figure 3

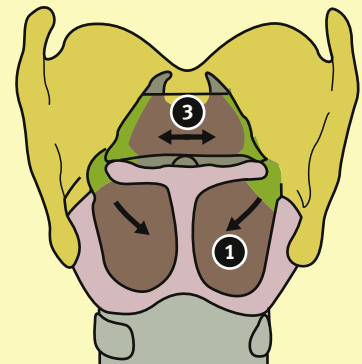
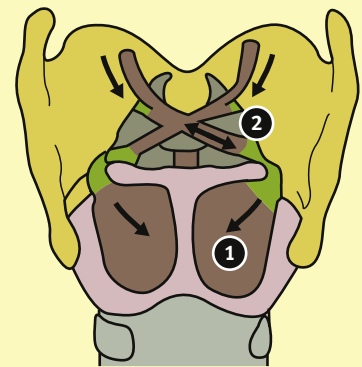
Intrinsic muscles of the larynx

Posterior view

Posterior cricoarytenoid (1) abducts/opens cords

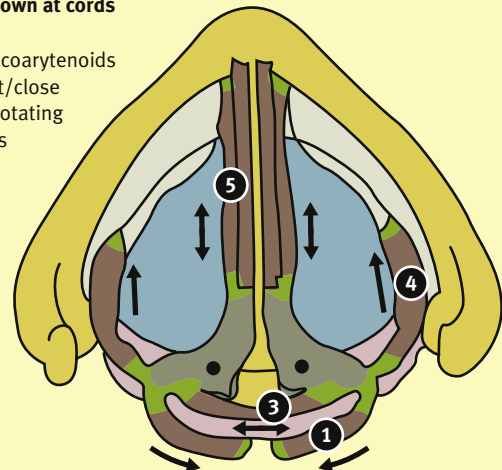
Oblique arytenoids (2) close cords by drawing together arytenoids. They extend into the aryepiglottic fold as aryepiglotticus to close the aditus

Transverse arytenoid (3) closes cords by drawing together arytenoids



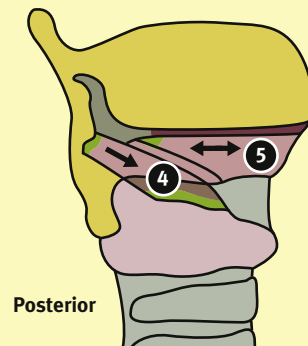
Looking down at cords

Lateral cricoarytenoids (4) adduct/close cords by rotating arytenoids medially



Lateral view

Thyroarytenoids (5) and vocalis loosen cords by drawing together the thyroid cartilage and arytenoids



Reproduced with permission from Whitaker RH, Borley NR. Instant anatomy. Oxford: Blackwell, 2005

Figure 4

Semon's law describes the effects of different injuries to the recurrent laryngeal nerve, and is the result of the relative strength of the adductor muscles to the abductor muscles (Figure 5).

Complete transection of the nerve causes complete paralysis, leaving the cords half abducted and half adducted (cadaveric position). The subject cannot speak or cough.

Trauma without transection results in partial paralysis and leaves the cords adducted as the posterior cricoarytenoid is most vulnerable. The subject cannot breathe.

If the damage is unilateral then the contralateral cord can partially compensate. If it is bilateral, it is life threatening.

Blood supply

The blood supply is derived from the external carotid, which gives off the superior and inferior thyroid arteries, which themselves give off the superior and inferior laryngeal arteries. The subclavian artery also supplies the larynx.

The trachea

The trachea is an elastic structure which stretches on inspiration. It is formed by C-shaped cartilaginous incomplete rings, with the defect posteriorly, joined together by the trachealis muscle. It is lined by ciliated pseudo-stratified columnar epithelium and is supplied by the inferior thyroid artery and veins and the bronchial arteries. Nerve supply is from the vagus and recurrent laryngeal nerves for pain and secreto-motor functions, and from the sympathetic nerves to blood vessels and smooth muscle.

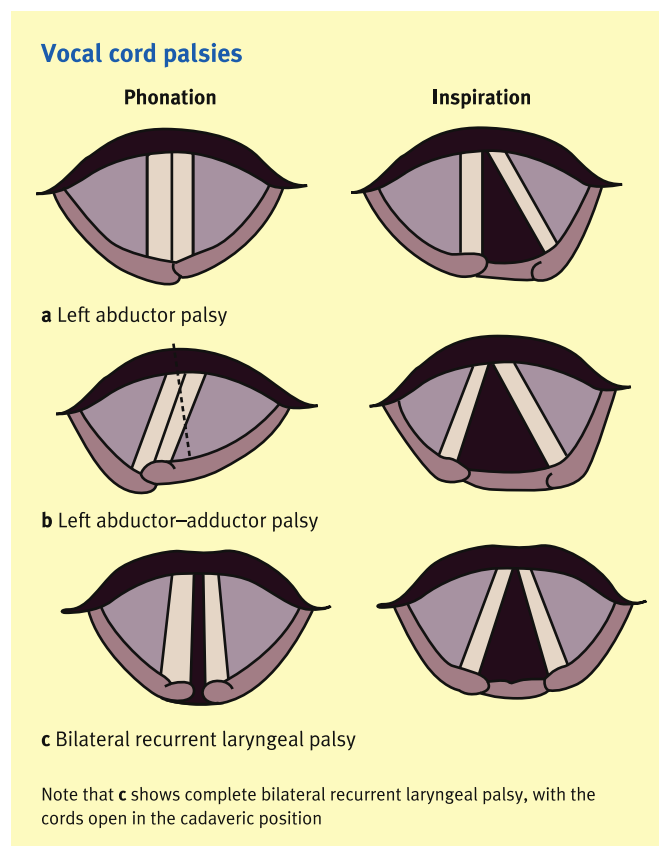


Figure 5

Relations (Figure 6)

- *Anterior:* inferior thyroid veins, anterior jugular arch, inferior mesenteric artery, thymus, sternum, sternohyoid, sternothyroid, left brachiocephalic veins.
- *Posterior:* oesophagus, recurrent laryngeal nerves.
- *Lateral:* carotid sheath, lateral lobes of the thyroid to the sixth ring.

Cricothyrotomy and tracheostomy

A cricothyrotomy is made by making a slit or small hole anteriorly in the relatively avascular cricothyroid membrane. A formal tracheostomy is made in the second or third tracheal ring by cutting a hole, often after dividing the thyroid isthmus if done surgically. The inferior thyroid veins and brachiocephalic vessels can get in the way and make this difficult.

Main bronchi

The right and left main bronchi differ from each other in the following ways:

- *right:* wider, shorter, more vertical, 2–3 cm long
- *left:* narrower, longer, more horizontal, 5 cm long.

This is the basis for two clinical points:

1. Inhaled foreign bodies are more likely to enter the right main bronchus.

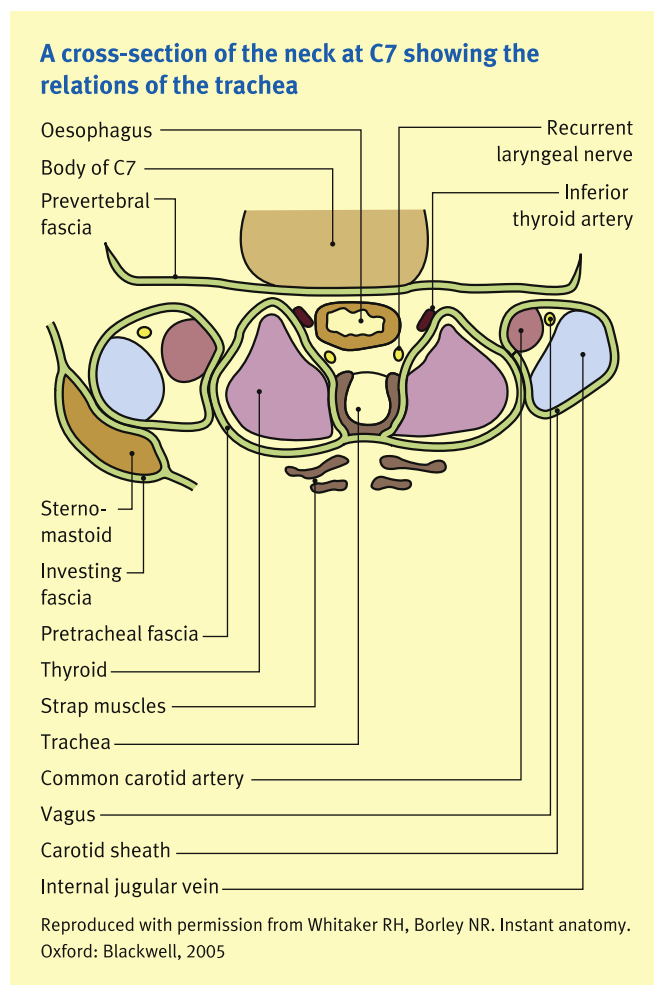


Figure 6

2. The correct placement of a double-lumen tracheal tube is more likely to be successful if the bronchial part is inserted into the left main bronchus rather than the right.

The bronchi are supplied by the bronchial arteries from the aorta, and drained by the azygos vein on the right and the hemiazygos vein on the left. There is also some drainage via the bronchial and pulmonary veins, which contributes to physiological shunt.

Nerve supply is autonomic from the pulmonary plexus at the hilum.

- The parasympathetic supply vasodilates, bronchoconstricts, increases secretions and is responsible for sensation.
- The sympathetic supply vasoconstricts, bronchodilates via β_2 - receptors, and suppresses secretions via α -receptors. ◆

FURTHER READING

Calder I, Pearce R. Core topics in airway management. 2nd edn. Cambridge University Press, ISBN 978 0511079566; 2010.

Ellis H, Feldman SJ, Harrop-Griffiths W. Anatomy for anaesthetists. 8th edn. Wiley-Blackwell, ISBN 978 1405106634; 2004.

Whitaker R, Borley N. Instant anatomy. 4th edn. Wiley-Blackwell, ISBN 978 1405199612; 2010.